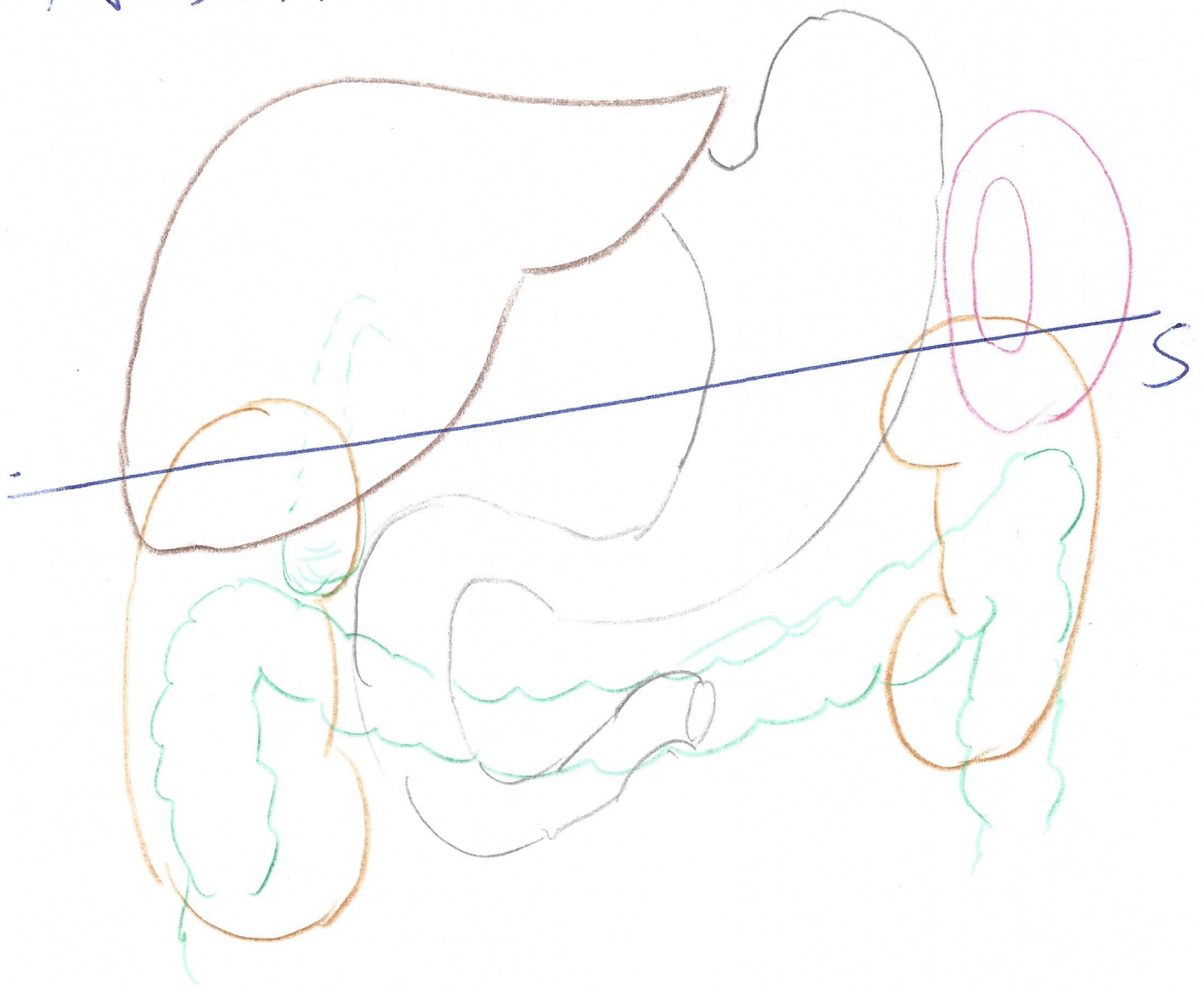
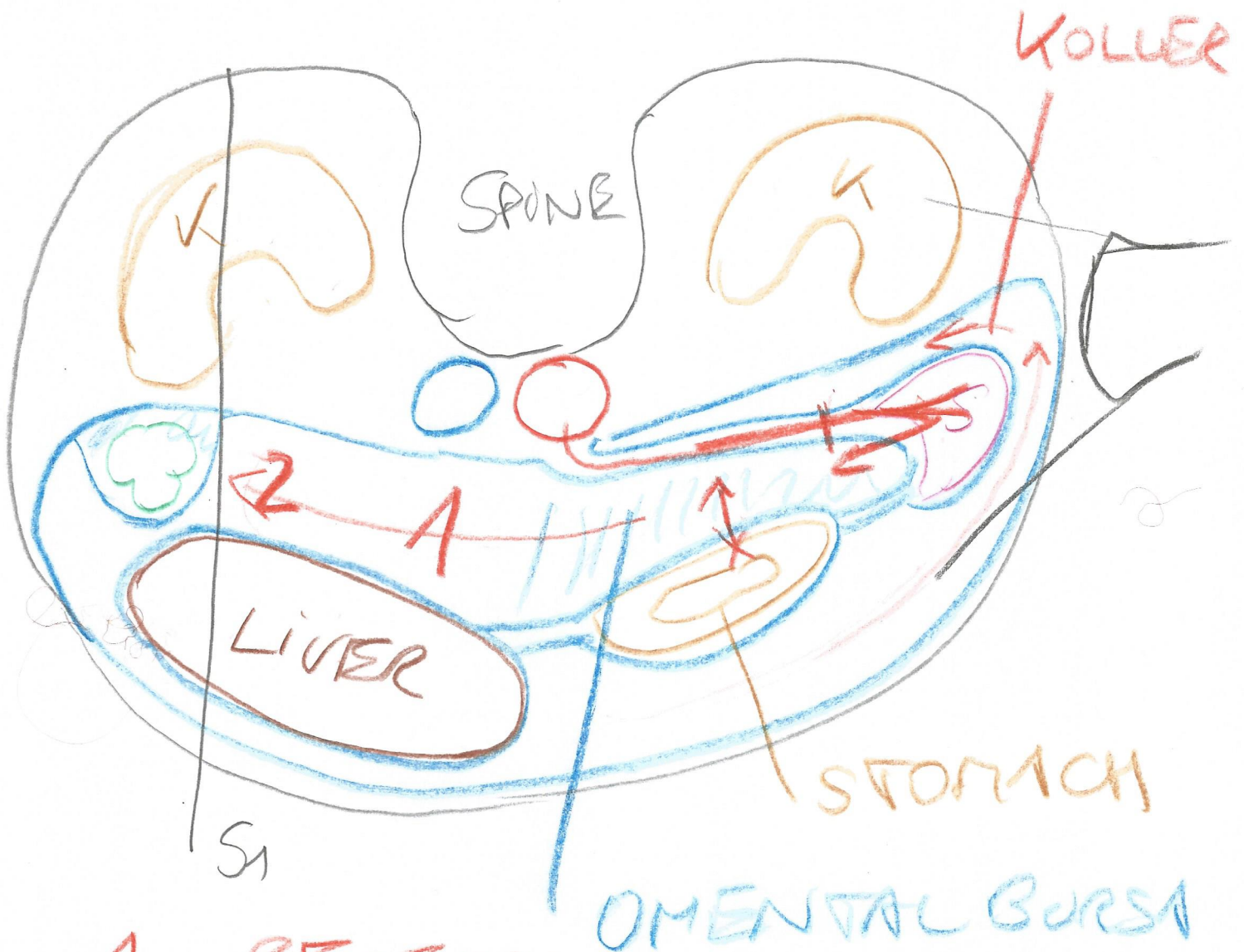


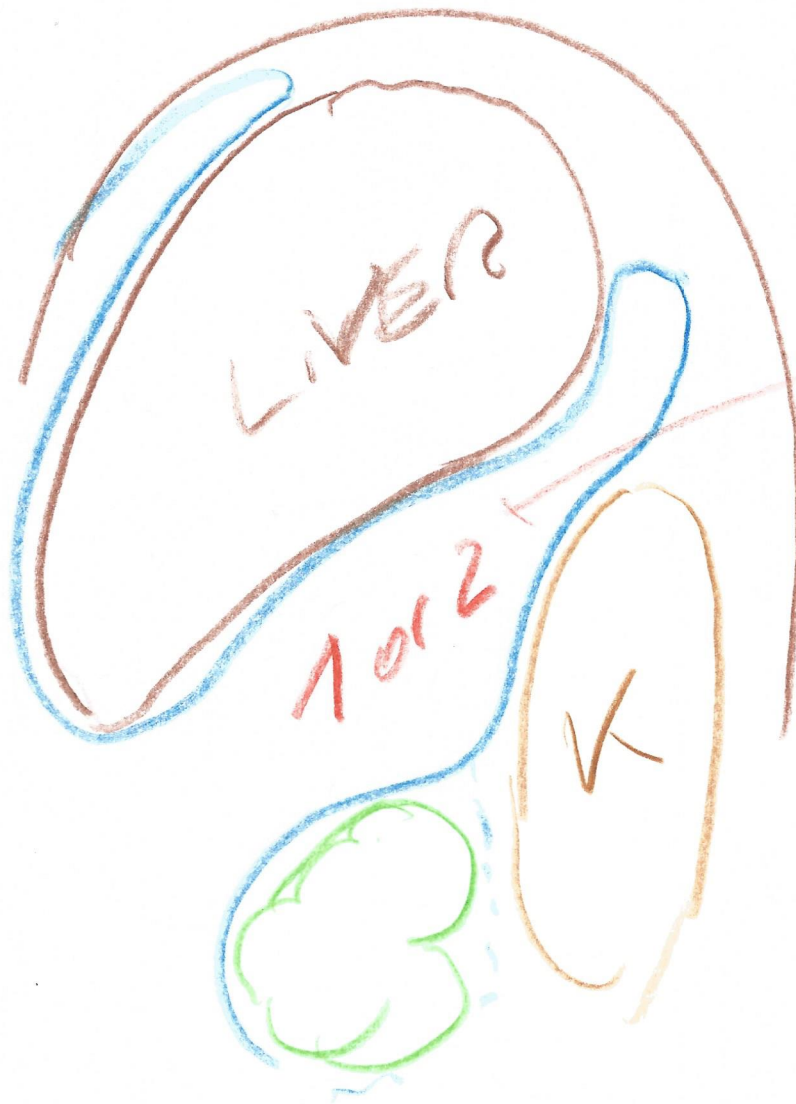# ABDOMINAL CAVITY



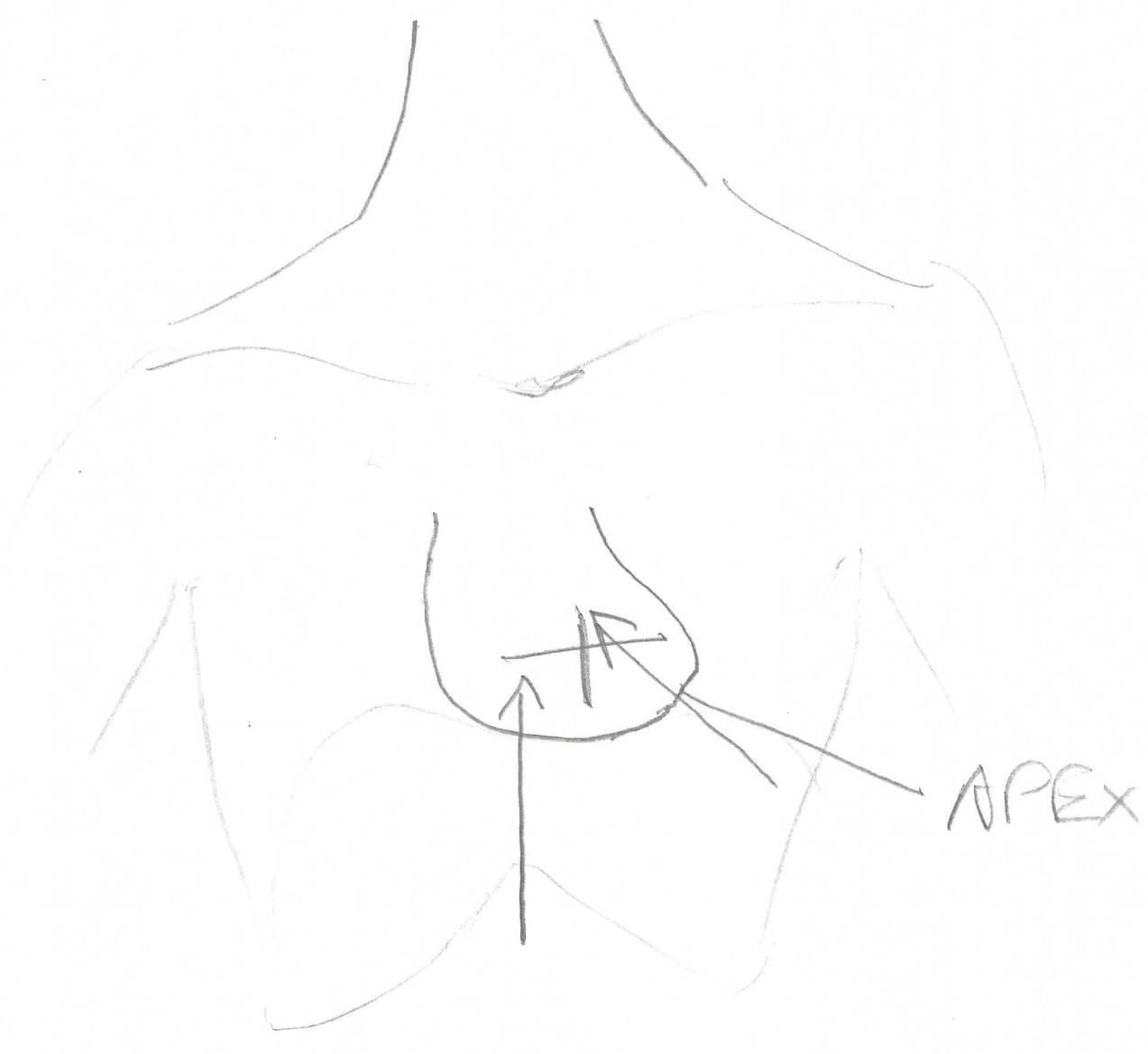
dorsal



- 1... RECESSUS  
HEPATORENALIS  
MORISON
- 2... REC. HEPATORENO COLICUS

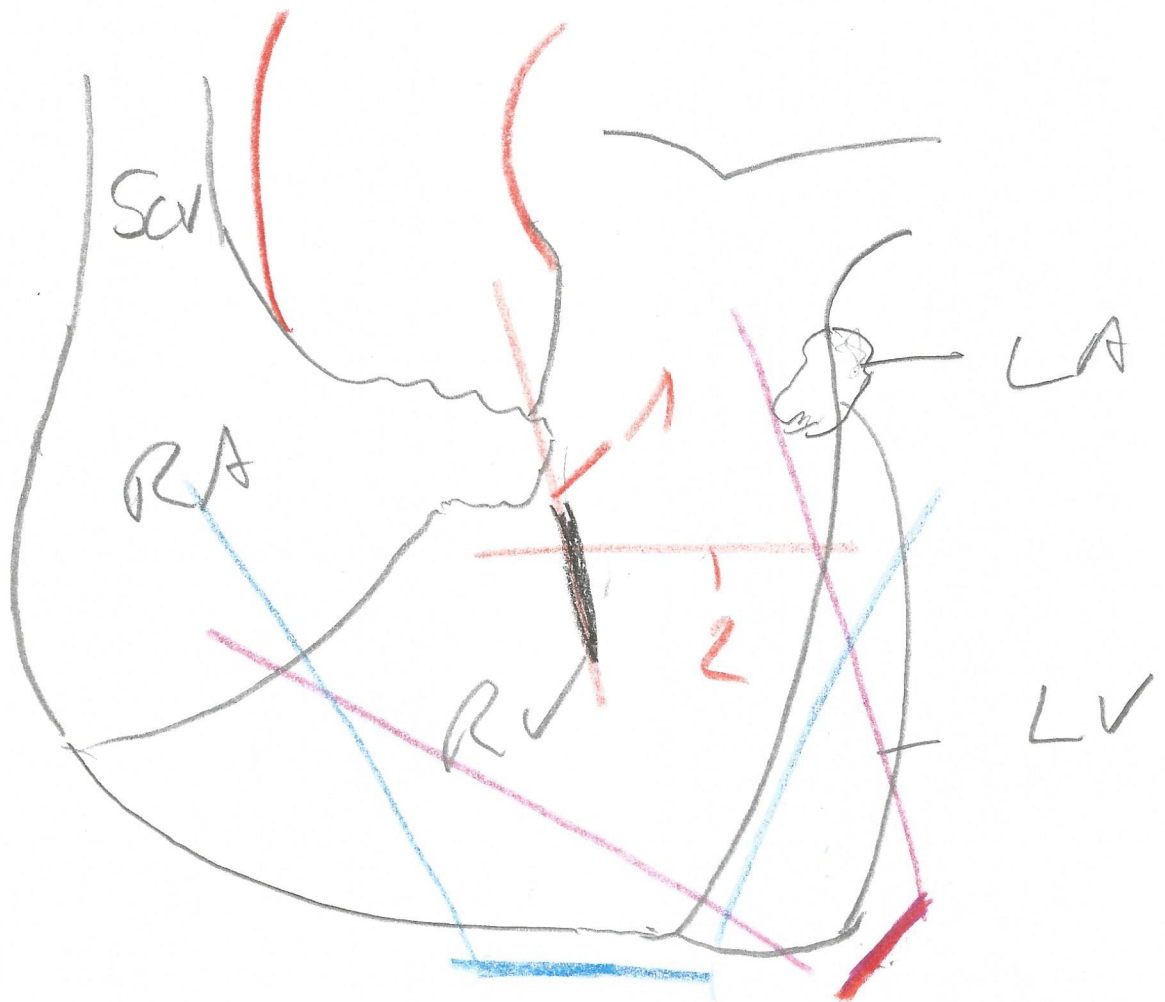


MORISON



# SURFACES

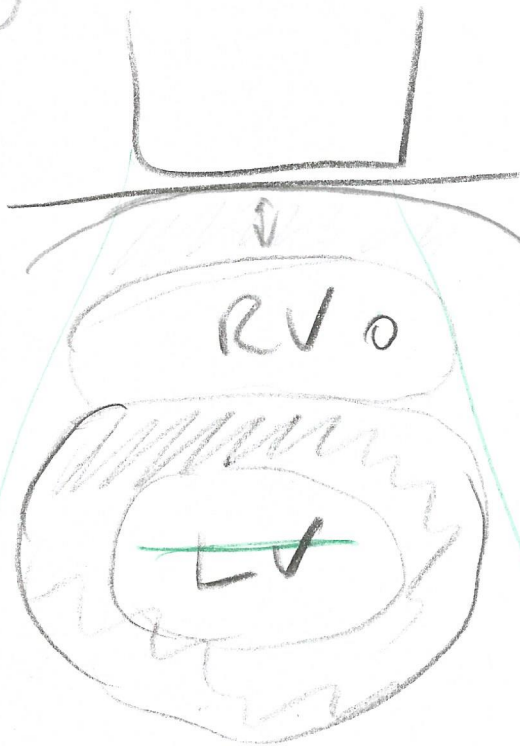STERNO COSTAL F.  
LATERAL F.  
DORSAL F.



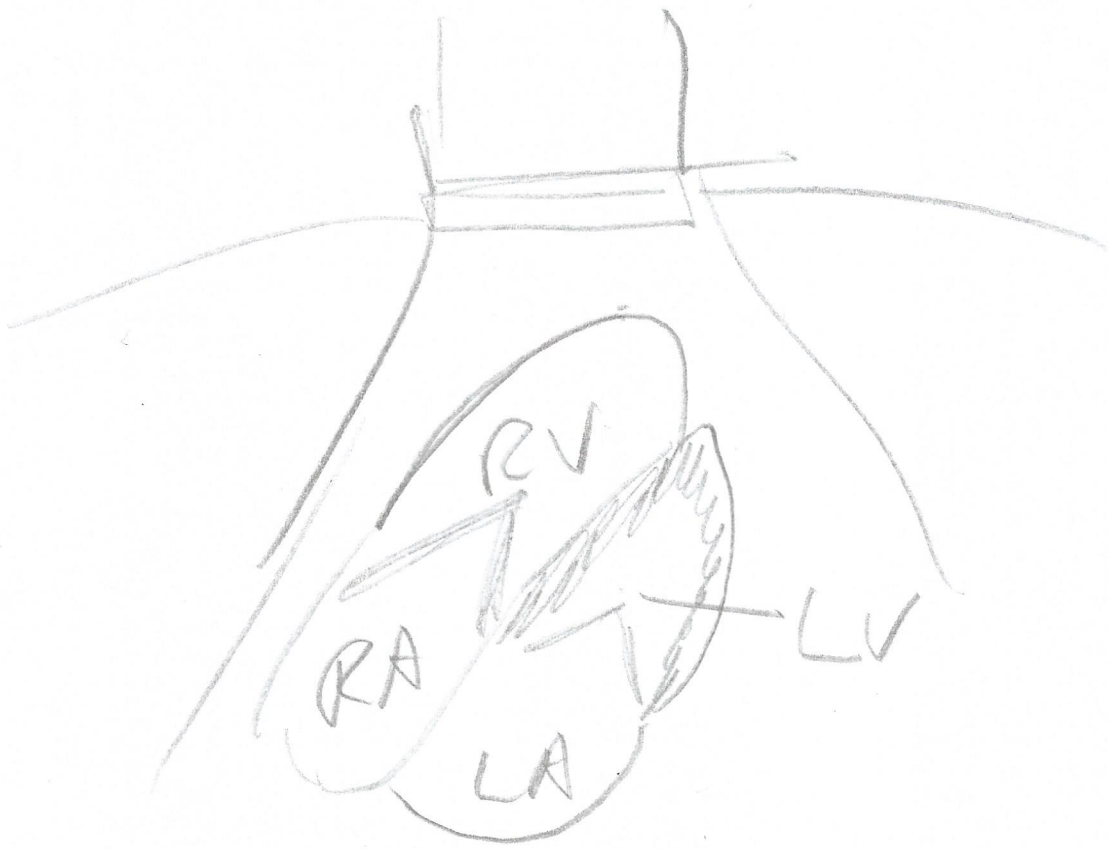1 + 2 → VENTRICLE

— 4 - CHAMBER

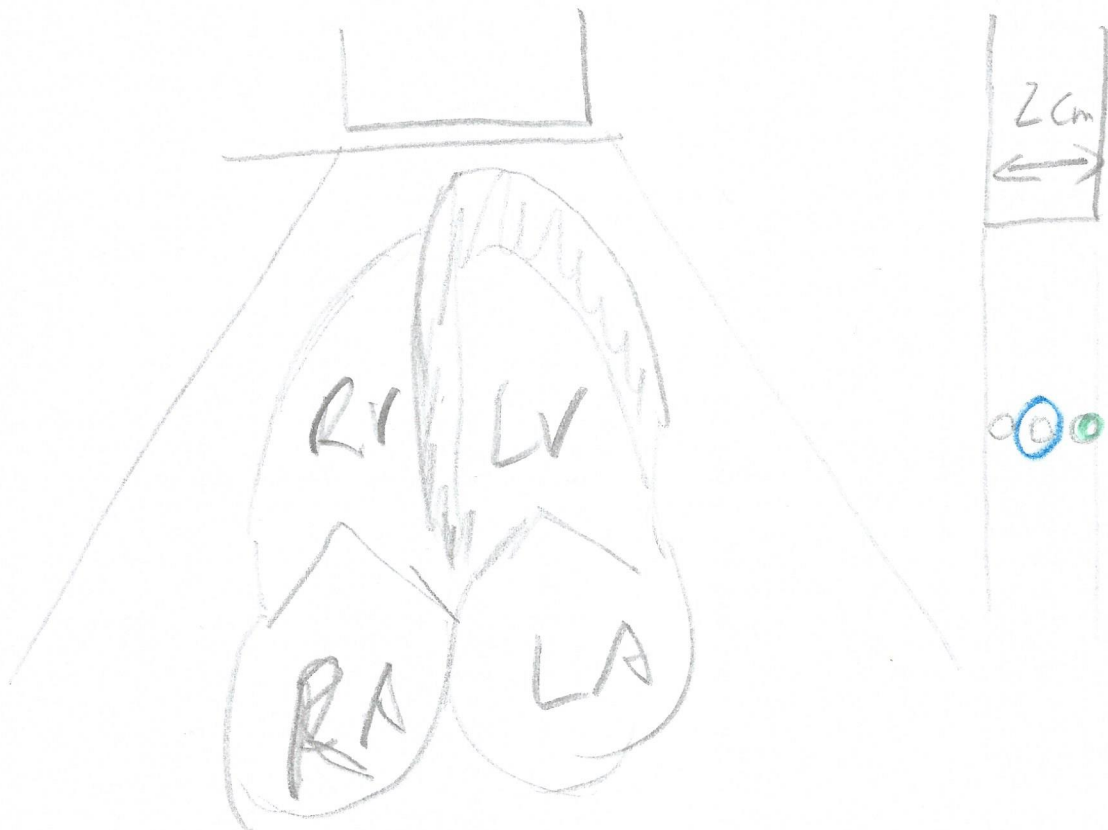# PARASTERNAL



# SUB XIPHOIDAL VIEW

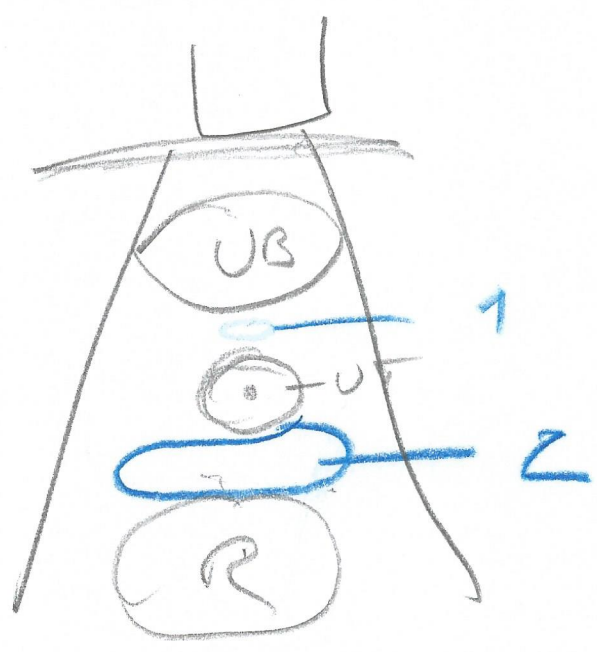
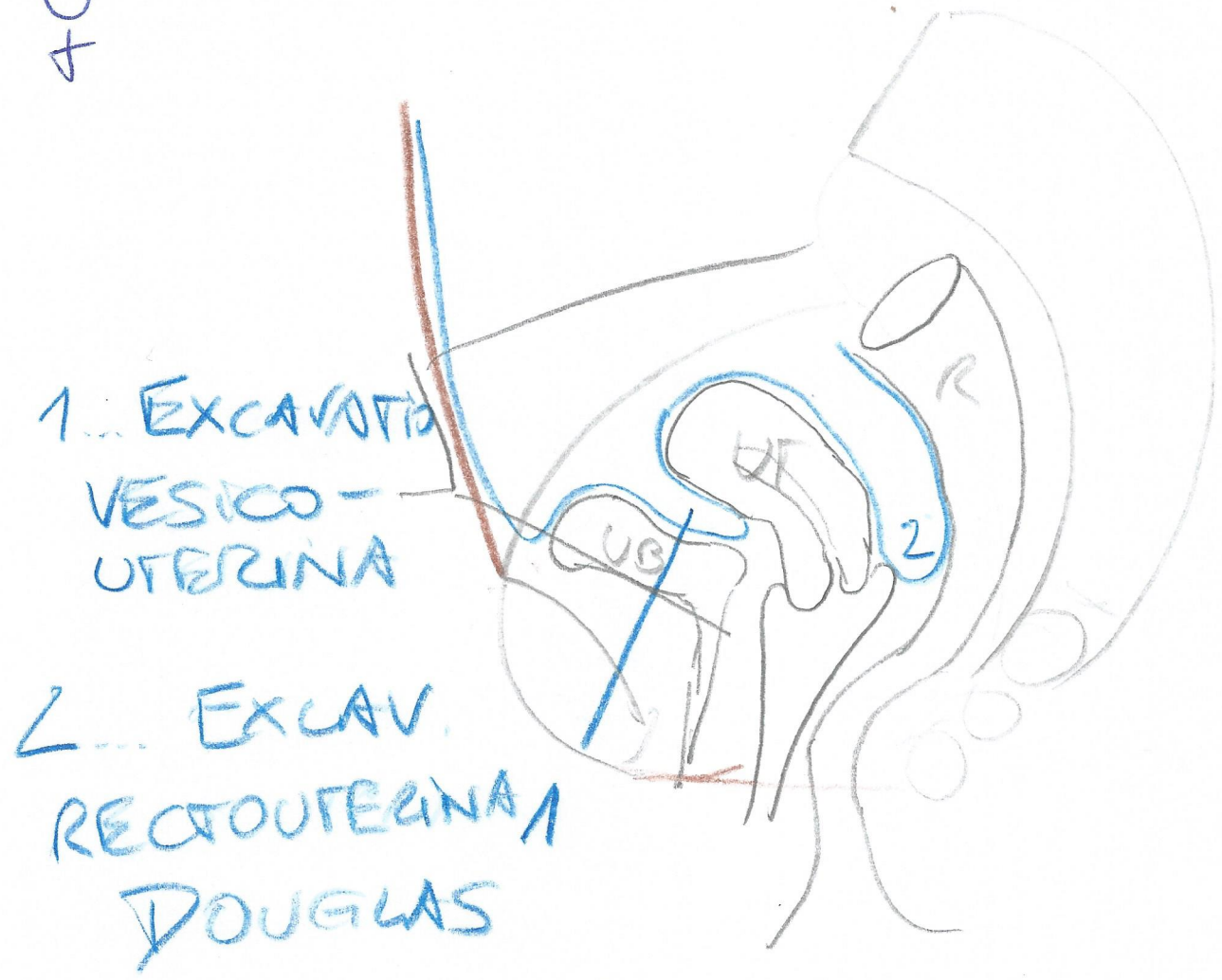


# APICAL 4 CHAMBER

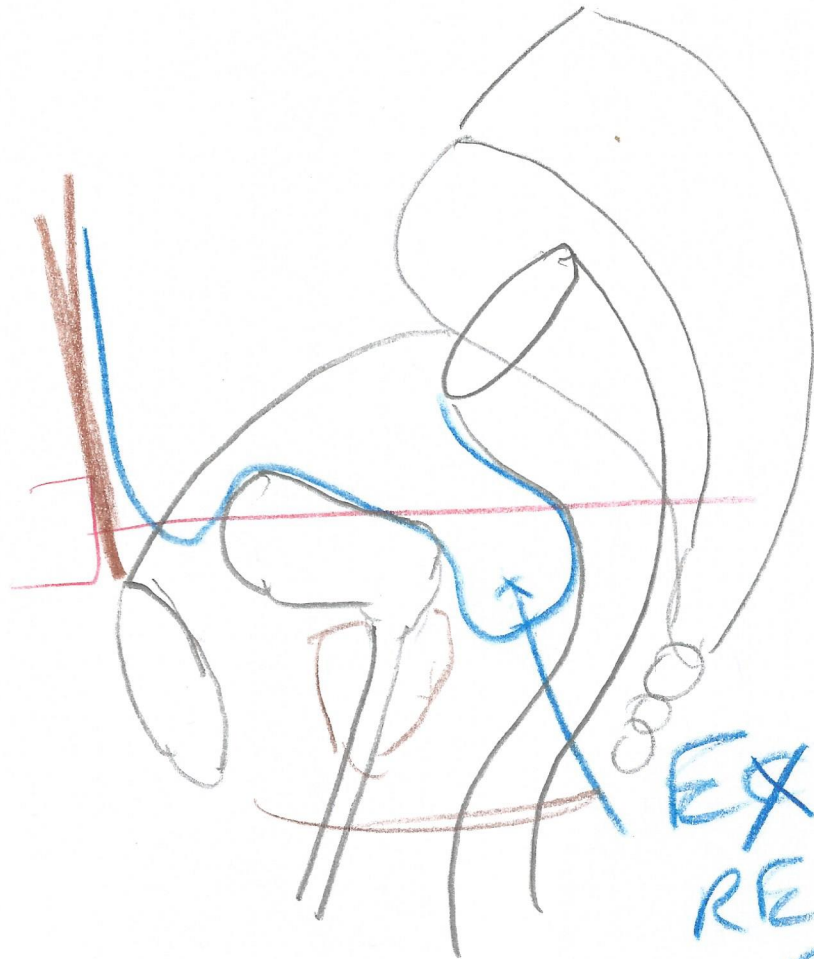

# PELVIC AREA

♀







EXCAVATIO  
RECTO-  
VESICATUS

